

Microbiology

Skin and Eye Infections

Mycoses of the Skin

LEARNING OBJECTIVES

- Identify the most common fungal pathogens associated with cutaneous and subcutaneous mycoses
- Compare the major characteristics of specific fungal diseases affecting the skin

Many fungal infections of the skin involve fungi that are found in the normal skin microbiota. Some of these fungi can cause infection when they gain entry through a wound; others mainly cause opportunistic infections in immunocompromised patients. Other fungal pathogens primarily cause infection in unusually moist environments that promote fungal growth; for example, sweaty shoes, communal showers, and locker rooms provide excellent breeding grounds that promote the growth and transmission of fungal pathogens.

Fungal infections, also called **mycoses**, can be divided into classes based on their invasiveness. Mycoses that cause superficial infections of the epidermis, hair, and nails, are called **cutaneous mycoses**. Mycoses that penetrate the epidermis and the dermis to infect deeper tissues are called **subcutaneous mycoses**. Mycoses that spread throughout the body are called **systemic mycoses**.

Tineas

A group of cutaneous mycoses called **tineas** are caused by **dermatophytes**, fungal molds that require keratin, a protein found in skin, hair, and nails, for growth. There are three genera of dermatophytes, all of which can cause cutaneous mycoses: ***Trichophyton***, ***Epidermophyton***, and ***Microsporum***. Tineas on most areas of the body are generally called **ringworm**, but tineas in specific locations may have distinctive names and symptoms (see Table 1 and Figure 1). Keep in mind that these names—even though they are Latinized—refer to locations on the body, not causative organisms.

Tineas can be caused by different dermatophytes in most areas of the body.

Tinea corporis (ringworm)	Body
Tinea capitis (ringworm)	Scalp
Tinea pedis (athlete's foot)	Feet
Tinea barbae (barber's itch)	Beard
Tinea cruris (jock itch)	Groin
Tinea unguium (onychomycosis)	Toenails, fingernails

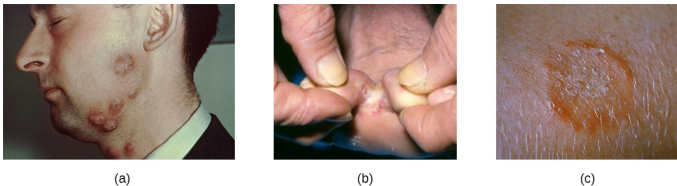


Figure 1. Tineas are superficial cutaneous mycoses and are common. (a) Tinea barbae (barber's itch) occurs on the lower face. (b) Tinea pedis (athlete's foot) occurs on the feet, causing itching, burning, and dry, cracked skin between the toes. (c) A close-up view of tinea corporis (ringworm) caused by *Trichophyton mentagrophytes*. (credit a, c: modification of work by Centers for Disease Control and Prevention; credit b: modification of work by Al Hasan M, Fitzgerald SM, Saoudian M, Krishnaswamy G)

Dermatophytes are commonly found in the environment and in soils and are frequently transferred to the skin via contact with other humans and animals. Fungal spores can also spread on hair. Many dermatophytes grow well in moist, dark environments. For example, **tinea pedis** (athlete's foot) commonly spreads in public showers, and the causative fungi grow well in the dark, moist confines of sweaty shoes and socks. Likewise, **tinea cruris** (jock itch) often spreads in communal living environments and thrives in warm, moist undergarments.

Tineas on the body (**tinea corporis**) often produce lesions that grow radially and heal towards the center. This causes the formation of a red

ring, leading to the misleading name of ringworm recall [the Clinical Focus case that started in Unicellular Eukaryotic Parasites](#).

Several approaches may be used to diagnose tinea. A **Wood's lamp** (also called a black lamp) with a wavelength of 365 nm is often used. When directed on a tinea, the ultraviolet light emitted from the Wood's lamp causes the fungal elements (spores and hyphae) to fluoresce. Direct microscopic evaluation of specimens from skin scrapings, hair, or nails can also be used to detect fungi. Generally, these specimens are prepared in a wet mount using a potassium hydroxide solution (10%–20% aqueous KOH), which dissolves the keratin in hair, nails, and skin cells to allow for visualization of the hyphae and fungal spores. The specimens may be grown on Sabouraud dextrose CC (chloramphenicol/cyclohexamide), a selective agar that supports dermatophyte growth while inhibiting the growth of bacteria and saprophytic fungi (Figure 2). Macroscopic colony morphology is often used to initially identify the genus of the dermatophyte; identification can be further confirmed by visualizing the microscopic morphology using either a slide culture or a sticky tape prep stained with lactophenol cotton blue.

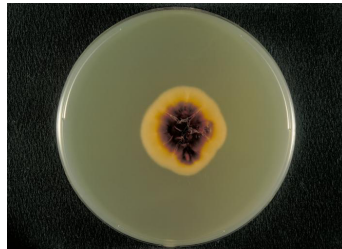

Figure 2. To diagnose tinea, the dermatophytes may be grown on a Sabouraud dextrose CC agar plate. This culture contains a strain of *Trichophyton rubrum*, one of the most common causes of tinea on various parts of the body. (credit: Centers for Disease Control and Prevention)

Various antifungal treatments can be effective against tinea. Allylamine ointments that include **terbinafine** are commonly used; **miconazole** and **clotrimazole** are also available for topical treatment, and **griseofulvin** is used orally.

THINK ABOUT IT

- Why are tinea, caused by fungal molds, often called ringworm?

Cutaneous Aspergillosis

Another cause of cutaneous mycoses is ***Aspergillus***, a genus consisting of molds of many different species, some of which cause a condition called **aspergillosis**. Primary cutaneous aspergillosis, in which the infection begins in the skin, is rare but does occur. More common is secondary cutaneous aspergillosis, in which the infection begins in the respiratory system and disseminates systemically. Both primary and secondary cutaneous aspergillosis result in distinctive eschars that form at the site or sites of infection (Figure 3). Pulmonary aspergillosis will be discussed more thoroughly in [Respiratory Mycoses](#).

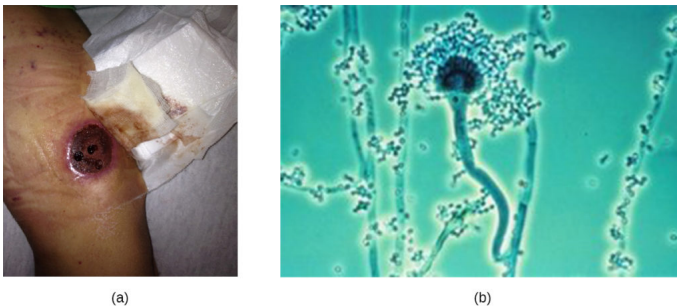


Figure 3. (a) Eschar on a patient with secondary cutaneous aspergillosis. (b) Micrograph showing a conidiophore of *Aspergillus*. (credit a: modification of work by Santiago M, Martinez JH, Palermo C, Figueroa C, Torres O, Trinidad R, Gonzalez E, Miranda Mde L, Garcia M, Villamarzo G; credit b: modification of work by U.S. Department of Health and Human Services)

Primary cutaneous aspergillosis usually occurs at the site of an injury and is most often caused by *Aspergillus fumigatus* or *Aspergillus flavus*. It is usually reported in patients who have had an injury while working in an agricultural or outdoor environment. However, opportunistic infections can also occur in health-care settings, often at the site of intravenous catheters, venipuncture wounds, or in association with burns, surgical wounds, or occlusive dressing. After candidiasis,

aspergillosis is the second most common hospital-acquired fungal infection and often occurs in immunocompromised patients, who are more vulnerable to opportunistic infections.

Cutaneous aspergillosis is diagnosed using patient history, culturing, histopathology using a skin biopsy. Treatment involves the use of antifungal medications such as **voriconazole** (preferred for invasive aspergillosis), **itraconazole**, and **amphotericin B** if itraconazole is not effective. For immunosuppressed individuals or burn patients, medication may be used and surgical or immunotherapy treatments may be needed.

THINK ABOUT IT

- Identify the sources of infection for primary and secondary cutaneous aspergillosis.

Candidiasis of the Skin and Nails

Candida albicans and other yeasts in the genus *Candida* can cause skin infections referred to as cutaneous candidiasis. *Candida* spp. are sometimes responsible for **intertrigo**, a general term for a rash that occurs in a skin fold, or other localized rashes on the skin. *Candida* can also infect the nails, causing them to become yellow and harden (Figure 4).

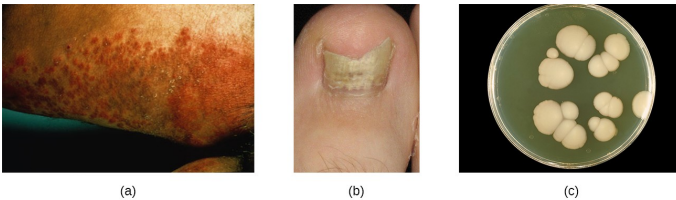


Figure 4. (a) This red, itchy rash is the result of cutaneous candidiasis, an opportunistic infection of the skin caused by the yeast *Candida albicans*. (b) Fungal infections of the nail (tinea unguium) can be caused by

dermatophytes or *Candida* spp. The nail becomes yellow, brittle, and prone to breaking. This condition is relatively common among adults. (c) *C. albicans* growing on Sabouraud dextrose agar. (credit a: modification of work by U.S. Department of Veterans Affairs; credit c: modification of work by Centers for Disease Control and Prevention)

Candidiasis of the skin and nails is diagnosed through clinical observation and through culture, Gram stain, and KOH wet mounts. Susceptibility testing for anti-fungal agents can also be done. Cutaneous candidiasis can be treated with topical or systemic azole antifungal medications. Because candidiasis can become invasive, patients suffering from HIV/AIDS, cancer, or other conditions that compromise the immune system may benefit from preventive treatment. Azoles, such as **clotrimazole**, **econazole**, **fluconazole**, **ketoconazole**, and **miconazole**; **nystatin**; **terbinafine**; and **naftifine** may be used for treatment. Long-term treatment with medications such as **itraconazole** or **ketoconazole** may be used for chronic infections. Repeat infections often occur, but this risk can be reduced by carefully following treatment recommendations, avoiding excessive moisture, maintaining good health, practicing good hygiene, and having appropriate clothing (including footwear).

Candida also causes infections in other parts of the body besides the skin. These include vaginal yeast infections (see [Fungal Infections of the Reproductive System](#)) and oral thrush (see [Microbial Diseases of the Mouth and Oral Cavity](#)).

THINK ABOUT IT

- What are the signs and symptoms of candidiasis of the skin and nails?

Sporotrichosis

Whereas cutaneous mycoses are superficial, **subcutaneous mycoses** can spread from the skin to deeper tissues. In temperate regions, the

most common subcutaneous mycosis is a condition called **sporotrichosis**, caused by the fungus *Sporothrix schenckii* and commonly known as **rose gardener's disease** or **rose thorn disease** (recall "**Every Rose Has Its Thorn**" in **Physical Defenses**). Sporotrichosis is often contracted after working with soil, plants, or timber, as the fungus can gain entry through a small wound such as a thorn-prick or splinter. Sporotrichosis can generally be avoided by wearing gloves and protective clothing while gardening and promptly cleaning and disinfecting any wounds sustained during outdoor activities.

Sporothrix infections initially present as small ulcers in the skin, but the fungus can spread to the lymphatic system and sometimes beyond. When the infection spreads, **nodules** appear, become necrotic, and may ulcerate. As more lymph nodes become affected, abscesses and ulceration may develop over a larger area (often on one arm or hand). In severe cases, the infection may spread more widely throughout the body, although this is relatively uncommon.

Sporothrix infection can be diagnosed based upon histologic examination of the affected tissue. Its macroscopic morphology can be observed by culturing the mold on potato dextrose agar, and its microscopic morphology can be observed by staining a slide culture with lactophenol cotton blue. Treatment with **itraconazole** is generally recommended.

THINK ABOUT IT

- Describe the progression of a *Sporothrix schenckii* infection.

MYCOSES OF THE SKIN

Cutaneous mycoses are typically opportunistic, only able to cause

infection when the skin barrier is breached through a wound. Tineas are the exception, as the dermatophytes responsible for tineas are able to grow on skin, hair, and nails, especially in moist conditions. Most mycoses of the skin can be avoided through good hygiene and proper wound care. Treatment requires antifungal medications. Table 2 summarizes the characteristics of some common fungal infections of the skin.

Table 2. Mycoses of the Skin

Disease	Pathogen	Signs and Symptoms	Transmission	Ant Dru
Aspergillosis (cutaneous)	<i>Aspergillus fumigatus</i> , <i>Aspergillus flavus</i>	Distinctive eschars at site(s) of infection	Entry via wound (primary cutaneous aspergillosis) or via the respiratory system (secondary cutaneous aspergillosis); commonly a hospital-acquired infection	Itraconazole, voriconazole, amphotericin B.
Candidiasis (cutaneous)	<i>Candida albicans</i>	Intertrigo, localized rash, yellowing of nails	Opportunistic infections in immunocompromised patients	Azoles
Sporotrichosis (rose gardener's disease)	<i>Sporothrix schenckii</i>	Subcutaneous ulcers and abscesses; may spread to a large area, e.g., hand or arm	Entry via thorn prick or other wound	Itraconazole
Tineas	<i>Trichophyton</i> spp., <i>Epidermophyton</i> spp., <i>Microsporum</i> spp.	Itchy, ring-like lesions (ringworm) at sites of infection	Contact with dermatophytic fungi, especially in warm, moist environments conducive to fungal growth	Tertianolol, miconazole, clotrimazole, griseofulvin

KEY CONCEPTS AND SUMMARY

- **Mycoses** can be **cutaneous, subcutaneous, or systemic**.
- Common cutaneous mycoses include **tineas** caused by **dermatophytes** of the genera *Trichophyton*, *Epidermophyton*, and *Microsporum*. **Tinea corporis** is called **ringworm**. Tineas on other parts of the body have names associated with the affected body part.
- **Aspergillosis** is a fungal disease caused by molds of the genus *Aspergillus*. Primary cutaneous aspergillosis enters through a break in the skin, such as the site of an injury or a surgical wound; it is a common hospital-acquired infection. In secondary cutaneous aspergillosis, the fungus enters via the respiratory system and disseminates systemically, manifesting in lesions on the skin.
- The most common subcutaneous mycosis is **sporotrichosis** (rose gardener's disease), caused by *Sporothrix schenckii*.
- Yeasts of the genus *Candida* can cause opportunistic infections of the skin called **candidiasis**, producing **intertrigo**, localized rashes, or yellowing of the nails.

MULTIPLE CHOICE

_____ is a superficial fungal infection found on the head.

- Tinea cruris
- Tinea capitis
- Tinea pedis
- Tinea corporis

Show Answer

For what purpose would a health-care professional use a Wood's lamp for a suspected case of ringworm?

- a. to prevent the rash from spreading
- b. to kill the fungus
- c. to visualize the fungus
- d. to examine the fungus microscopically

[Show Answer](#)

Sabouraud dextrose agar CC is selective for _____.

- a. all fungi
- b. non-saprophytic fungi
- c. bacteria
- d. viruses

[Show Answer](#)

The first-line recommended treatment for sporotrichosis is _____.

- a. itraconazole
- b. clindamycin
- c. amphotericin
- d. nystatin

[Show Answer](#)

FILL IN THE BLANK

The most common subcutaneous mycosis in temperate regions is _____.

[Show Answer](#)

THINK ABOUT IT

1. What yeasts commonly cause opportunistic infections?
2. What steps might you recommend to a patient for reducing the risk of developing a fungal infection of the toenails?

[Previous](#)

[Next](#)